

# Dysphagia: Difficulty swallowing or difficulty moving food from mouth to stomach

Jeri A. Logemann, Ph.D.  
Ralph and Jean Sundin Professor  
Department of Communication Sciences and Disorders  
Northwestern University  
2240 Campus Drive  
Evanston, IL 60208  
e-mail: [j-logemann@northwestern.edu](mailto:j-logemann@northwestern.edu)  
Phone: 847-491-2490  
Fax: 847-491-5692

Individuals with dysphagia or difficulty swallowing often complain of coughing when eating, food sticking when eating, throat clearing when eating, feeling of something remaining in their mouth or throat after swallowing, and other discomfort related to eating. They may avoid food that is more difficult for them to swallow. Sometimes this happens so slowly that patients are not very self-aware of their problem. Dysphagia is common in people who are elderly or who have had a neurological event such as a stroke or structural damage such as treatment for head and neck cancer. Children and infants can also have swallowing disorders as a result of a birth defect, or of an acquired birth defect, or of an acquired or developmental neurologic disorder (Arvedson and Lefton-Greif 1998; Logemann 1998). Most of the information in this chapter applies to children and adults who have dysphagia, but not to infants who have not yet developed mature oral control.

In many cases, the cause of the swallowing problem is clear. The individual may have had a stroke, a head injury, a spinal cord injury, a diagnosed neurologic disease such as Parkinson's disease, amyotrophic lateral sclerosis, multiple sclerosis, etc (Bisch et al. 1994; Buchholz 1994a, b; Calcagno et al. 2002; Lazarus and Logemann 1987; Lazarus et al. 1996; Logemann 1998; Logemann et al. 2008; Robbins and Levine 1988). Or they may have developed a swallowing problem either before or after surgery to remove a cancerous tumor. There are also individuals who have dysphagia of unknown etiology. In most cases, these are related to an undiagnosed neurological problem. There are many reasons for swallowing problems and the first question the clinician seeing the patient should answer is, "What is the medical cause of the swallowing problem?" Very occasionally, swallowing disorders are psychologically based.

## Normal Swallowing

Normal swallowing involves rapid coordination of muscles and structures in the mouth, throat or pharynx, and esophagus. This coordination enables the food to first be chewed and reduced to a consistency ready for swallowing; it enables the swallow to shift from the oral stage, where the muscles in the mouth and tongue are breaking the food down to a consistency ready for swallow, to the pharynx, where a number of valves must open or close to direct the food into the esophagus. Those valves include the soft palate, or velopharyngeal area, which keeps food from entering the nose; the base of tongue, or the lowest part of the tongue which must make contact with the pharyngeal wall to generate pressure to drive food through the pharynx and into the

Deleted: JA Logemann Encyclopedia of Rehabilitation July 7 2008.doc ms  
7/7/08 . Page 3

Formatted: Font: 12 pt

esophagus; the larynx, or voice box, which must close to prevent food from going into the windpipe; and the upper esophageal sphincter, which must open at the correct moment to allow food into the esophagus. These valves in the pharynx are critical to normal swallow, protecting the airway and propelling food into the esophagus. Figure 1 illustrates these valves. All of these movements must occur within several seconds. Timely coordination is very important. The food must be pushed along with pressure generated by the tongue in the mouth, the lowest part of the tongue, the base of tongue, in the pharynx or throat, and the walls of the pharynx, which help contract sequentially, top to bottom, pushing the food to the esophagus where the esophageal muscles take over, contracting sequentially to push the food into the stomach. In order to treat a dysphagic patient effectively, the clinician must be able to diagnose the specific parts of the swallow that are damaged. Damage will vary, depending upon the cause of the swallow problem and the type of impairment to physical and neurological structures and functions. Swallowing is finished when food enters the stomach. Normal swallowing slows a bit as we get older, and there is a tendency to have slightly more food left in the throat as we age, but the amount is very small. Generally, the efficiency or safety of swallow does not change significantly in healthy individuals as we age (Logemann et al. 2000, 2002; Robbins et al. 1992, 1995).

### **Age Effects**

In general, however, dysphagia occurs with greater frequency in older patients as a result of the disorders of older patients. For example, Parkinson's disease occurs in large measure in patients who are over the age of 50. Similarly, patients who have suffered a stroke often have difficulty with swallowing, and most of these patients are over the age of 60.

### **Assessment**

The initial steps in assessment of swallowing include a careful history to assist in defining the reason for the patient's swallowing disorder, generally followed by a clinical evaluation, and then an instrumental assessment. The clinical assessment generally includes an evaluation of the patient's mouth, throat or pharynx, and larynx or voice box. The clinician, most often a speech-language pathologist with training in the area of evaluation and treatment of dysphagia, looks at the range of motion of structures, the speed of movement of structures, and the coordination of movement of the structures in the mouth and pharynx. These include the lips, palate, tongue, and larynx or voice box. The patient is usually asked to produce various voluntary movements with each structure as well as to produce some speech sounds, which require, like swallowing, coordination of all of these structures. Though speech and swallowing are very different, examining the patient's coordination for each function can often help the speech-language pathologist to define the components of the dysphagia or swallowing problem.

### **Instrumental Assessment**

The instrumental assessment of swallow allows the clinician to observe the exact appearance and coordination of movement of the structures in the mouth, throat or pharynx, and larynx. There are a number of instrumental assessments that enable the clinician to observe various aspects of the swallow directly. These are needed in order for the clinician to diagnose the specific type of swallowing problem the patient has and select the best treatment for them. The following are the most common types of assessment.

Deleted: JA Logemann Encyclopedia of Rehabilitation July 7 2008.doc ms  
7/7/08 . Page 3

Formatted: Font: 12 pt

## Modified Barium Swallow

The modified barium swallow (MBS) or videofluoroscopic examination is a moving x-ray of the oral and pharyngeal aspects of swallow and can be extended to view the esophagus. Figure 2 shows a lateral radiographic view of the oral and pharyngeal area. In this test, the patient is given measured amounts of thin liquids (1 ml, 3 ml, 5 ml, 10 ml, cup drinking), pudding, and food that requires chewing (usually a piece of cookie) to chew and swallow so that clinicians can define abnormalities in the swallow. This test enables the clinician to observe which parts of the swallow are normal and which muscles are functioning normally or abnormally. In addition to defining the exact nature of the patient's swallow disorder, the patient can be asked to try various treatment techniques so that the effects of these techniques can be examined and the best techniques for that patient are defined. This test takes approximately 15 minutes and involves very little x-ray exposure (Beck and Gayler 1990; Chan et al. 2002; Logemann 1993; Wright et al. 1998).

## Endoscopy (FEES)

Fiberoptic endoscopic examination of swallowing (FEES) is not an x-ray study. It utilizes a small diameter tube placed through the nose and into the pharynx to visualize the pharynx before, during, and after swallowing. Figure 3 illustrates the placement of the endoscopic tube in the lateral plane. A small amount of anesthetic may be used in the nose to make the procedure entirely comfortable. Patients are then given colored foods and liquids of varying consistency as in the MBS procedure and swallowing is observed. The food is seen as it comes over the back of the tongue and into the throat or pharynx and is observed until the food disappears into the esophagus. One disadvantage of endoscopy is its inability to view the oral stage and the esophageal stage of swallowing. However, it does enable the clinician to determine whether or not there is any food that goes into the trachea (aspiration) and whether there is any food left in the pharynx after the swallow. An advantage of endoscopy is that the equipment can be brought to the patient's bedside and the pharyngeal stage of swallow observed without using x-ray. FEES can be repeated numerous times with no adverse effects.

## Manometry

Manometry is a technique used to measure pressures in the pharynx and/or esophagus during the swallow. While x-ray can be used to observe indirect effects of pressure adequacy during swallow, manometry enables quantification of swallowing pressures. Manometry involves placing a small flexible tube through the nose and down into the pharynx and esophagus. The tube contains small pressure sensors that register pressure throughout the swallow. Pressure is a very important component to an efficient swallow. If pressure is not adequate at any level of the pharynx, food will remain at that level, rather than being pushed along to the next level of the digestive tract. Patients usually perceive this as food or fluid left over after their swallow. Sometimes the modified barium swallow and manometry are done at the same time.

## Ultrasound

Ultrasound is an imaging procedure that visualizes soft tissue by using high frequency sound waves. It does not utilize x-ray. Unfortunately, the only portion of the swallow that can be clearly imaged with ultrasound is the mouth or oral cavity. The pharynx is the most critical part of the swallow, so ultrasound does not enable us to truly evaluate disorders of the pharynx. It is

Deleted: JA Logemann Encyclopedia of Rehabilitation July 7 2008.doc ms  
7/7/08 . Page 3

Formatted: Font: 12 pt

useful if the individual patient has specific oral disorders that can be visualized with ultrasound. Because it does not use x-ray, it can be used repeatedly to evaluate the oral function during swallow.

## Treatment

Once the managing clinician has defined the patient's swallowing disorders, they will plan the patient's treatment. Treatment is different for every patient, depending upon the cause of their swallowing disorder and the nature of the swallow disorder – that is, the specific movements that are not normal. One treatment will not work for every patient with dysphagia and abnormalities in swallow must be treated in the context of the patient's diagnosis. For example, patients with Parkinson's disease do best with active exercise, while patients with dysphagia as a result of amyotrophic lateral sclerosis will fatigue and lose function with active exercise. This reflects the importance of understanding the underlying diagnosis or cause of the swallowing disorder as well as the abnormality in the swallow anatomy or physiology. Behavioral treatment, including the techniques described above, is usually the first treatment choice for dysphagic patients because these procedures are not invasive and they are often highly successful.

Whenever possible, the clinician can introduce treatment strategies immediately during the diagnostic study to determine how well they work to improve the patient's swallow (Martin-Harris et al. 2000; Rasley et al. 1993; Veis et al. 2000). In general, the order in which treatments are introduced to the patient during a radiographic modified barium swallow is: 1) changes in head or neck posture for those who aspirate or get food into their trachea; 2) introducing foods with greater sensory input, such as carbonated drinks, for those swallowing disorders that are sensory based. Introducing these foods can speed triggering of the pharyngeal swallow or facilitate recognition of food in the mouth; 3) swallowing maneuvers are voluntary changes in selected aspects of the swallow that patients can be taught that will make their swallow more normal; and, finally, 4) changing diet consistency to facilitate an easier swallow. All of these four procedures and the specific techniques included in each of these four can be introduced during MBS or other instrumental assessments and have the potential to immediately improve the patient's swallow function. There are also exercise programs that can make a major improvement in the patient's swallow. These, however, do require time to take effect, so that doing it immediately during an instrumental procedure will not show the effectiveness of the procedure. Included in the exercise category are exercises to improve the opening of the upper esophageal sphincter into the esophagus (Shaker et al. 1997; 2002), the strength of the tongue (Robbins et al. 2005; 2007), the coordination of the swallow (Lazarus et al. 1993), and others.

There are a number of experimental procedures that have not been shown to have consistent effectiveness, including electrical stimulation, deep pharyngeal neuromuscular stimulation, and others. These are all experimental procedures at this point, as they do not have enough strong data to prove their effectiveness in facilitating improved swallowing, but are currently under study (Kiger et al. 2006; Ludlow et al. 2007). Patients can certainly utilize these procedures under the direction of a qualified therapist, usually a speech-language pathologist, but the patient should be made aware that these are experimental procedures. There is a great deal of research ongoing on the treatment of swallowing disorders. Patients should be kept informed about this research on treatment and keep an eye out for new, validated procedures. However, some new procedures are "sold" too aggressively before data are available that strongly reflect the success

Deleted: JA Logemann Encyclopedia of Rehabilitation July 7 2008.doc ms  
7/7/08 . Page 3

Formatted: Font: 12 pt

or failure of these procedures. The patient should be encouraged to ask their therapist if the procedure(s) they are using is well established or if they are experimental at this time.

## Outcomes

The only way to know definitively whether a treatment works or not is to collect information on the patient's swallow physiology before a treatment is begun and again after the treatment is completed. However, many patients with dysphagia experience significant spontaneous recovery such that within two to three weeks of their diagnosis causing the dysphagia, such as stroke, their swallowing has returned to a functional status, where their swallow may be a bit slower than a normal swallow but does not exhibit aspiration but is functional and only exhibits a mild amount of residue left behind after the swallow. This is one of the problems with research in dysphagia. Many clinicians are confused when providing therapy early on and seeing tremendous improvement. While this improvement may, in fact, relate to therapy, it is impossible to separate spontaneous recovery from exercise effect in patients of this kind.

Over 80% of all patients with dysphagia will exhibit recovery to full oral intake; some of this recovery may be spontaneous. Good outcomes are supported by good diagnosis and good treatment but also careful planning of the patient's treatment to select those treatments that have evidence to support their effectiveness.

## Other Treatment Procedures

However, there are patients that may receive surgical procedures to improve their swallowing such as those with disorders of the cricopharyngeal upper esophageal sphincter (UES). Surgical procedures may include cutting a muscle at the top of the junction into the esophagus (cricopharyngeal myotomy), or a procedure to move a cartilage within the larynx to improve airway protection and eliminate aspiration. Use of botox injections into the muscle at the top of the esophagus, the cricopharyngeus, may improve swallow in some patients, though usually this is a small proportion of individuals. In addition to surgical procedures, there may be medication used to improve the swallow. For example, in a few cases, anti-Parkinsonian medication may improve the swallow in the Parkinson patient with dysphagia. Medications may also improve swallowing for patients with myasthenia gravis, a neurologic disease affecting the ability of muscles to contract. However, these kinds of medications are not applicable to a large number of patients.

## References

Ali GN, Wallace KN, Schwartz R, DeCarle DJ, Zagami AS, Cook IJ. 1996. Mechanisms of oral-pharyngeal dysphagia in patients with Parkinson's disease. *Gastroenterology* 110:383-392.

Arvedson J, Lefton-Greif M. 1998. *Pediatric Videofluoroscopic swallow studies*. San Antonio (TX): The Psychological Corporation.

| Beck T J, Gayler BW. 1990. Image quality and radiation levels in videofluoroscopy for swallowing studies: A review. *Dysphagia* 5:118-128.

Deleted: JA Logemann Encyclopedia of Rehabilitation July 7 2008.doc ms  
7/7/08 . Page 3

Formatted: Font: 12 pt

- Bisch EM, Logemann JA, Rademaker AW, et al. 1994. Pharyngeal effects of bolus volume, viscosity and temperature in patients with dysphagia resulting from neurologic impairment and in normal subjects. *Journal of Speech and Hearing Research* 37:1041-49.
- Buchholz DW. 1994a. Dysphagia associated with neurologic disorders. *Acta Oto-Rhino Laryngologica Belgica* 48:143-155.
- Buchholz DW. 1994b. Postpolio dysphagia. *Dysphagia* 9:99-100.
- Calcagno P, Ruoppolo G, Grass MG, De Vincentiis M, Paolucci S. 2002. Dysphagia in multiple sclerosis -- prevalence and prognostic factors. *Acta Neurologica Scandinavia* 105(1):40-43.
- Chan C, Chan LK, Lam HS. 2002. Scattered radiation level during videofluoroscopy for swallowing study. *Clinical Radiology* 57(7):614-616.
- Kiger M, Brown CS, Watkins L. 2006. Dysphagia management: An analysis of patient outcomes using VitalStim™ therapy compared to traditional swallow therapy. *Dysphagia* 21(4):243-253.
- Lazarus C, Logemann JA. 1987. Swallowing disorders in closed head trauma patients. *Archives of Physical Medicine and Rehabilitation* 68:79-87.
- Lazarus C, Logemann JA, Gibbons P. 1993. Effects of maneuvers on swallowing function in a dysphagic oral cancer patient. *Head and Neck* 15(5):419-424.
- Lazarus CL, Logemann JA, Pauloski BR, Colangelo LA, Kahrilas PJ, Mittal BB, Pierce M. 1996. Swallowing disorders in head and neck cancer patients treated with radiotherapy and adjuvant chemotherapy. *Laryngoscope* 106:1157-1166.
- Logemann JA. 1993. A manual for videofluoroscopic evaluation of swallowing. 2nd ed. Austin (TX): Pro-Ed.
- Logemann JA. 1998. Evaluation and treatment of swallowing disorders. 2nd ed. Austin (TX): Pro-Ed.
- Logemann JA, Pauloski BR, Rademaker AW, Colangelo LA, Kahrilas PJ, Smith CH. 2000. Temporal and biomechanical characteristics of oropharyngeal swallow in younger and older men. *Journal of Speech, Language, and Hearing Research* 43:1264-1274.
- Logemann JA, Pauloski BR, Rademaker AW, Kahrilas PJ. 2002. Oropharyngeal swallow in younger and older women: Videofluoroscopic analysis. *Journal of Speech, Language, and Hearing Research* 45:434-444.
- Logemann JA, Gensler G, Robbins JA, Lindblad A, Brandt D, Hind J, Kosek S, Dikeman K, Kazandjian M, Gramigna GD, Lundy D, McGarvey-Toler S, Gardner PJM. 2008. A randomized study of three interventions for aspiration of thin liquids in patients with

Deleted: JA Logemann Encyclopedia of Rehabilitation July 7 2008.doc ms  
7/7/08 . Page 3

Formatted: Font: 12 pt

dementia and Parkinson's disease. *Journal of Speech, Language, and Hearing Research* 51:173-183.

Ludlow C, Humbert I., Saxon K, Poletto C, Sonies B, Crujido L. 2007. Effects of surface electrical stimulation both at rest and during swallowing in chronic pharyngeal dysphagia. *Dysphagia* 22(1):1-10.

Martin-Harris B, Logemann JA, McMahon S, Schleicher M, Sandidge J. 2000. Clinical utility of the modified barium swallow. *Dysphagia* 15:136-141.

Rasley A, Logemann JA, Kahrilas PJ, Rademaker AW, Pauloski BR, Dodds WJ. 1993. Prevention of barium aspiration during videofluoroscopic swallowing studies: Value of change in posture. *American Journal of Roentgenology* 160:1005-1009.

Robbins J, Gangnon RE, Theis SM, Kays SA., Hewitt AL, Hind JA. 2005. The effects of lingual exercise on swallowing in older adults. *Journal of the American Geriatrics Society* 53(9):1483-1489.

Robbins J, Hamilton J, Lof GL, Kempster GB. 1992. Oropharyngeal swallowing in normal adults of different ages. *Gastroenterology* 103:823-829.

Robbins J, Kayes SA, Gangnon RE, Hind JA, Hewitt AL, Gentry LR, Taylor AJ. 2007. The effects of lingual exercise in stroke pts with dysphagia. *Archives of Physical Medicine and Rehabilitation* 88(2):150-158.

Robbins J, Levine R. 1988. Swallowing after unilateral stroke of the cerebral cortex: Preliminary experience. *Dysphagia* 3:11-17

Robbins J, Levine R, Wood J, Roecker E, Luschei E. 1995. Age effects on lingual pressure generation as a risk factor for dysphagia. *Journal of Gerontology: Medical Sciences* 50A:M257-M262.

Shaker R, Easterling C, Kern M, Nitschke T, Massey B, Daniels S, Grande B, Kazandjian M, Dikeman K. 2002. Rehabilitation of swallowing by exercise in tube fed patients with pharyngeal dysphagia secondary to abnormal UES opening. *Gastroenterology* 122(5):1314-1321.

Shaker R, Kern M, Bardan E, Taylor A, Stewart E T, Hoffman RG, Arndorfer RC, Hofmann C, Bonnevier J. 1997. Augmentation of deglutitive upper esophageal sphincter opening in the elderly by exercise. *American Journal of Physiology* 272 (Gastrointestinal Liver Physiology, 35):G1518-G1522.

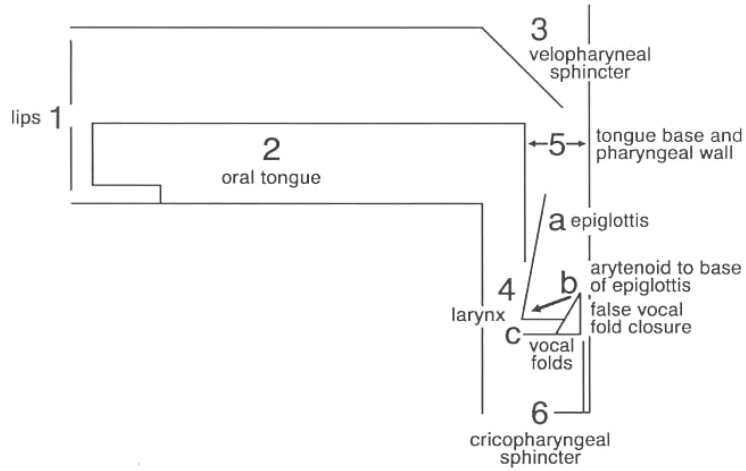
Veis S, Logemann JA, Colangelo LA. 2000. Effects of three techniques on maximum posterior movement of the tongue base. *Dysphagia* 15:142-145.

Wright RE, Boyd CS, Workman A. 1998. Radiation doses to patients during videofluoroscopy. *Dysphagia* 13(2):113-115.

Deleted: JA Logemann Encyclopedia of Rehabilitation July 7 2008.doc ms  
7/7/08 Page 3

Formatted: Font: 12 pt

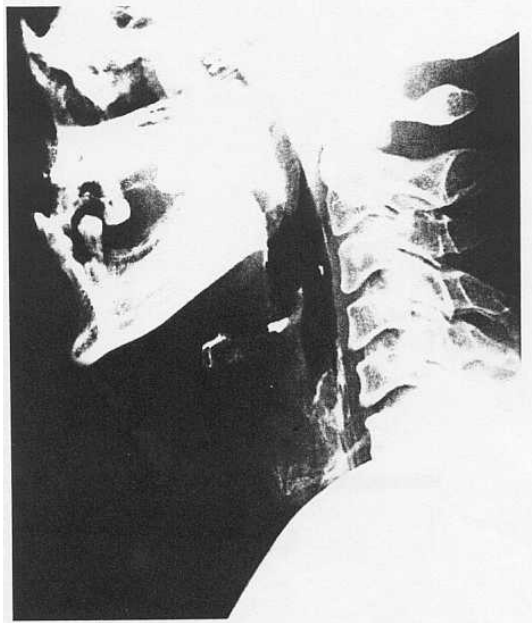Figure 1. A diagram of the valves of the upper aerodigestive tract involved in swallowing.



Deleted: JA Logemann Encyclopedia of Rehabilitation July 7 2008.doc ms  
7/7/08 Page 3

Formatted: Font: 12 pt

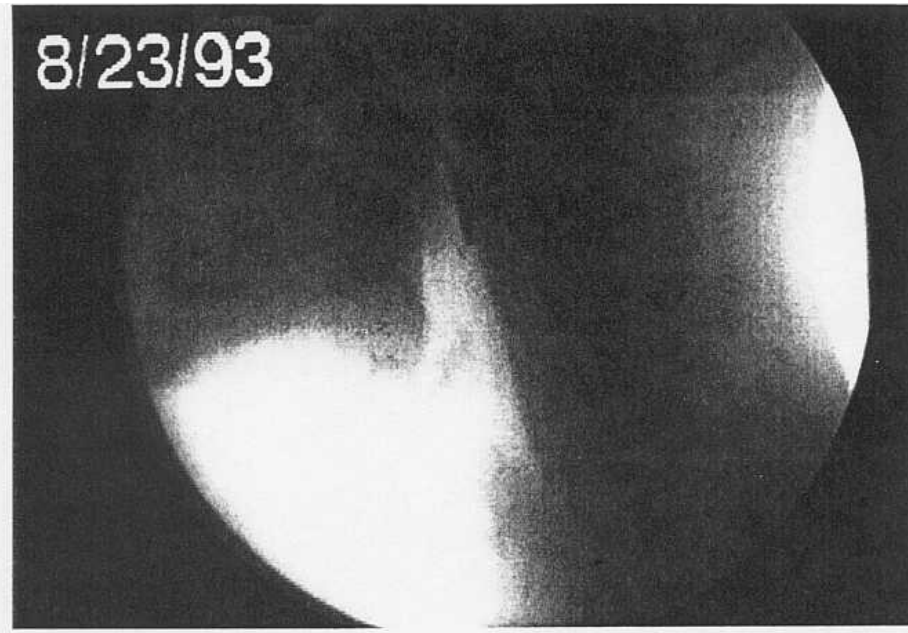
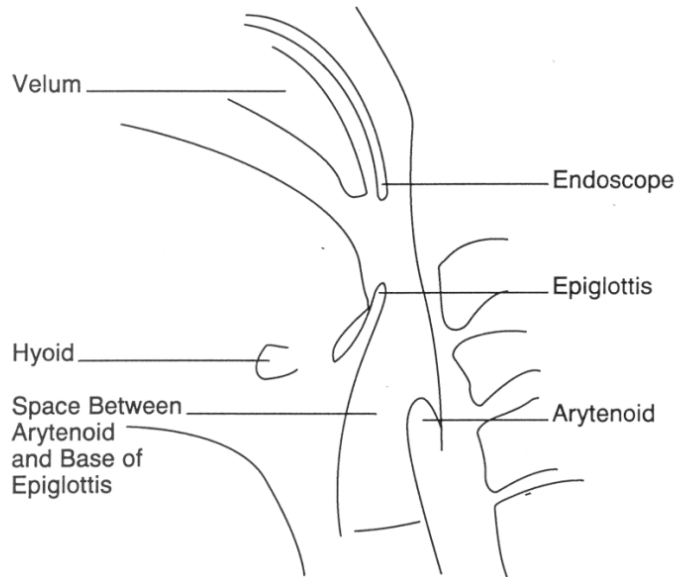
Figure 2. Lateral radiographic view of the oral cavity and pharynx.



Deleted: JA Logemann Encyclopedia of Rehabilitation July 7 2008.doc ms  
7/7/08 . Page 3

Formatted: Font: 12 pt

Figure 3. Lateral views of the flexible endoscopic tube placement behind the soft palate to view the pharynx before and after swallowing.



Deleted: JA Logemann Encyclopedia of Rehabilitation July 7 2008.doc ms 7/7/08 Page 3

Formatted: Font: 12 pt